

## CBCT: A VALUABLE IMAGING TECHNIQUE IN ENDODONTICS

Rakhee Modak<sup>1</sup>, Shubhangi Gaikwad<sup>1</sup>, Amit Mhapuskar<sup>1</sup>, Jyoti Mandlik<sup>2</sup>

<sup>1</sup>Dept of Oral Medicine and Radiology, Bharati Vidyapeeth Deemed University Dental College and Hospital, Pune, INDIA

<sup>2</sup>Department of Conservative Dentistry and Endodontics, Bharati Vidyapeeth Deemed University Dental College and Hospital Pune, INDIA

### ABSTRACT

Radiographic examination represents essential part of contemporary management of endodontic problems, from diagnosis & treatment planning to outcome evaluation. Intra-oral & panoramic radiographic assessment have inherent limitations that 3-dimensional anatomy (3D) is compressed in 2 dimensional (2D) image, superimpositions of anatomic structures resulting in geometric distortion of area and anatomic noise that can hide region of interest. Cone beam computed tomography (CBCT) is relatively new method that produces three dimensional (3D) information of maxillofacial skeleton including teeth & their surrounding tissue with lower effective radiation dose than traditional CT scan. CBCT imaging can be used in all phases of treatment including diagnosis, treatment planning, during treatment phase & through post treatment assessment & follow up. CBCT has great potential in managing endodontic problems, as well as for assessing root fractures, apical periodontitis, resorptions, perforations, canal anatomy & nature of alveolar bone topography around teeth. The purpose of this article is to review the use of CBCT imaging in the diagnosis & treatment planning & assessing the outcome of endodontic complications & advantages of CBCT over conventional radiography.

Received on: 22<sup>nd</sup>-February-2016

Revised on: 25<sup>th</sup>-April-2016

Accepted on: 7<sup>th</sup>- March-2016

Published on: 11<sup>th</sup>- June-2016

#### KEY WORDS

Periapical Radiograph (PR);  
Cone beam computed  
tomography (CBCT); Apical  
periodontitis; Periapical lesions;  
Root canal treatment; Vertical  
Root fractures.

\*Corresponding author: Email: [drakheemodak@gmail.com](mailto:drakheemodak@gmail.com); Tel.: + 91-9209252677

### INTRODUCTION

Imaging is an important diagnostic adjunct to the clinical assessment of the dental patient. The introduction of panoramic radiography in the 1960s and its widespread adoption throughout the 1970s and 1980s heralded major progress in dental radiology. However, intraoral and extraoral procedures, used individually or in combination, suffer from the same inherent limitations of all planar two-dimensional (2D) projections: magnification, distortion, superimposition and misrepresentation of structures. Computed tomography was available for 3-dimensional dental imaging in the 1980s, but due to the high cost, limited access, and radiation exposure, utilization was limited to management of craniofacial anomalies, complex surgeries, and other unique dental situations. In 1988, cone beam computerized tomography (CBCT) was introduced to dentistry. This technology offered 3-dimensional visualization and more complex and more accurate imaging compared to analog and digital radiographs [1,2]

### CONE BEAM COMPUTED TOMOGRAPH

A CBCT scanner for dentomaxillofacial use was developed in the late 1990s and, since the very first report, [3] use of this technique has become widespread in dentistry. Using CBCT, a 3D volume of data is acquired in the course of a single sweep of the scanner. The technique is contingent upon a simple, direct relationship between the sensor and the source, which rotates synchronously 180—360° around the patient's head. The X ray beam, which is cone-shaped (hence the name of the technique), captures a cylindrical or spherical volume of data, described as the field of view (FOV). One of the major advantages of CBCT over computed tomography (CT) is the significantly lower effective radiation dose to which patients are exposed.[4] The dose depends on the region of the jaw to be scanned, the exposure settings of the CBCT scanner, the size of the FOV, the exposure time(s), the tube current (mA) and the energy/potential(kV) [5-7].

The use of CBCT technology in clinical dental practice provides a number of potential advantages for maxillofacial imaging.[8]

- **X-ray Beam limitation:**  
Reducing the size of the irradiated area by collimation of the primary X-ray beam to the area of interest minimizes the radiation dose. Most CBCT units can be adjusted to scan small regions for specific diagnostic tasks.
- **Image accuracy:**  
The volumetric data set comprises a 3D block of smaller cuboid structures, known as voxels, each representing a specific degree of X-ray absorption. The size of these voxels determines the resolution of the image. All CBCT units provide voxel resolutions that are isotropic- equal in all 3 dimensions. This produces sub-millimeter resolution ranging from 0.4 mm to as low as 0.076 mm. Because of this characteristic, subsequent secondary (axial, coronal, and sagittal) and multiplanar reformation (MPR) images achieve a level of spatial resolution accurate enough for endodontic measurements.
- **Rapid scan time:**  
Because CBCT acquires all projection images in a single rotation, scan time is rapid (10-70 seconds) and comparable to medical spiral MDCT systems and panoramic radiography, which is desirable because motion artifacts due to subject movement are reduced.
- **Dose reduction:**  
Published reports indicate that the effective dose of radiation (average range 36.9-50.3 $\mu$ Sv) is significantly reduced by up to 98% compared with conventional fan beam CT systems. This reduces the effective patient dose to approximately that of a film based periapical survey of the dentition (13-100  $\mu$ Sv) or 4-15 times that of a single panoramic radiograph (2.9-11  $\mu$ Sv)

For most endodontic applications, limited volume CBCT is preferred over large volume CBCT for the following reasons:

- Increased spatial resolution to improve the accuracy of endodontic-specific tasks such as the visualization of small features including accessory canals, root fractures, apical deltas, calcifications, etc.
- Highest possible spatial resolution that provides a diagnostically acceptable signal-to-noise ratio for the task at hand.
- Decreased radiation exposure to the patient.
- Time savings due to smaller volume to be interpreted.

## APPLICATION OF CBCT IMAGING IN ENDODONTICS

### *Assessment of Root Canal Anatomy*

The success of endodontic treatment depends on the identification of all root canals so that they can be accessed, cleaned, shaped, and obturated [9]. The prevalence of a second mesiobuccal canal (MB2) in maxillary first molars has been reported to vary from 69% to 93% depending on the study method employed. Conventional radiographic techniques, at best, can only detect up to 55% of these configurations. Because of the 2D nature of conventional radiography, it does not consistently reveal the actual number of canals present in teeth. In several studies, CBCT imaging was superior in detecting the number of roots to PRs [10-12]. CBCT reconstructions are somewhat important in assessing teeth with an unusual number of roots, dilacerated teeth, and dens in dente [13-15]. Root morphology (ie, the number of root canals and whether they merge or not) can be visualized 3-dimensionally.

Different studies have used CBCT to study the root canal morphology of maxillary molars. Blattner et al [12] assessed the prevalence of second MB canals in extracted maxillary first and second molars in vitro. The teeth were sectioned axially to confirm the true number of root canals. In total, an 80% correlation was reported between CBCT findings and the results obtained by tooth sectioning. Neelakantan et al. [13] compared the efficacy of six methods (modified canal staining and clearing, CBCT, peripheral quantitative CT, spiral CT, digital radiography and contrast medium-enhanced digital radiography) in identifying the root canal systems of 95 teeth. Their results showed that CBCT was as accurate as the gold standard (a modified canal staining and clearing technique). 3D reconstructions of CBCT images allow clinicians to fully appreciate the internal endodontic anatomy of the root canal system in each type of tooth. CBCT images are also helpful in finding extra canals (Fig 1)

### *Detection of Apical Periodontitis*

CBCT scanning is a tomogram and eliminates anatomic noise, thus enabling the detection of radiolucent endodontic lesions before the buccal or lingual plate is demineralized [16,17]. Apical periodontitis (AP) is correctly identified with conventional radiographic methods when the disease is in an advanced stage according to the periapical index (40% demineralization). When lesions are small, CBCT imaging shows better diagnostic results [18-27]. CBCT software may be used to maximize the diagnostic yield of the captured data, as the reconstructed slices are geometrically accurate because pixels of CBCT images are isotropic. Therefore, periapical

lesions will not show changes in size or disappear on reconstructed scans as can happen with intraoral radiography as a result of poor irradiation geometry [24].

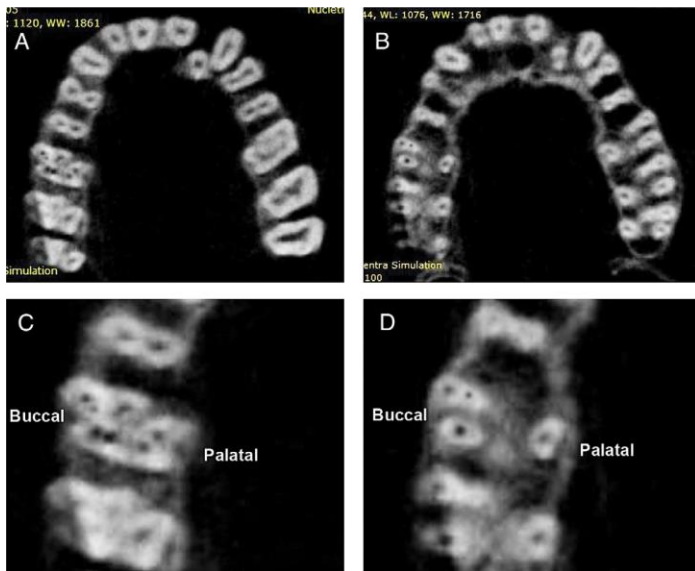


Fig:1.(A and B) CBCT images of #3 showing axial sections at the (A) cervical and (B) apical level. (C and D) Enlarged axial section CBCT images at the (C) cervical and (D) apical level showing three roots and seven canals.

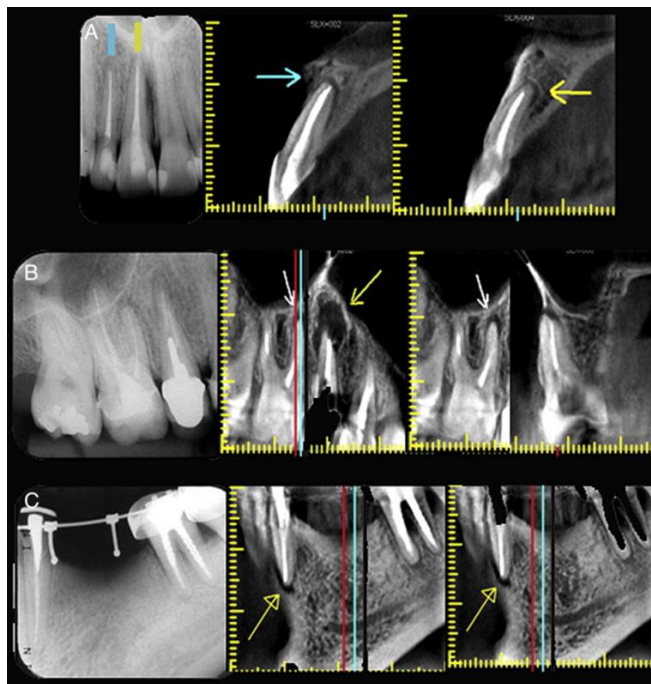


Fig:2. In x-ray periapical lesion is not seen in maxillary anterior but is clearly seen in CBCT image

Estrela et al.[16] compared the accuracy of CBCT, panoramic and periapical radiographs from a consecutive sample of 888 imaging exams of patients with endodontic infection (1,508 teeth) in the detection of apical periodontitis (AP). While a gold standard was not available, they found the detected prevalence of apical periodontitis to be significantly higher with CBCT. Bender and Seltzer [17,25] and Schwarz and Foster [26] showed that the size of the periapical lesion is often underestimated using periapical radiographs. CBCT

enables the detection of radiolucent endodontic lesions before the lingual or buccal plate is demineralized [19, 27, 28] Use of CBCT eliminates the superimposition of anatomical structures and is useful in identifying processes occurring within the cancellous bone. Both in vivo [16, 20, 29] and in-vitro [19,30] studies have shown that CBCT detects periapical lesions more effectively than periapical radiographs.

### **Pre-surgical Assessment**

CBCT is particularly recommended for diagnosis and treatment planning before endodontic surgery. The benefits of the use of CBCT during endodontic surgery include elimination of the superimposition of anatomic structures, such as the zygomatic buttress, alveolar bone, maxillary sinus and other roots, and early detection of the presence and dimensions of apical lesions and changes in apical bone density [19,31] The axial, coronal and sagittal planes obtained with CBCT scans also provide clinicians with a clear view of the anatomical relationship between root apices and neighboring structures, such as the mandibular canal, mental foramen and maxillary sinus [31-33]. CBCT imaging may play an important role in microsurgery on the palatal root of maxillary molars; the distance between the cortical bone plate and the palatal apex can be measured, and the presence of the maxillary sinus between the roots can be assessed [34].

### **Root Canal Treatment Quality Assessment**

The most important area in which CBCT can be applied in endodontics is in determining the outcome of treatment. Conventional and digital PRs have been widely used for follow-up after root canal treatment. However, in teeth with apical periodontitis, microscopic findings and radiographic examinations are often divergent [35]. Chronic periapical inflammation often persists for years after root canal filling, even in the absence of clinical symptoms and radiographic alterations [36,37]. The most recent literature demonstrates that the detection of periapical lesions following root canal treatment using CBCT is more accurate than that using radiographic evaluation [29, 38-41]. In a retrospective longitudinal cohort study, Fernández et al. [40] evaluated the outcome of endodontic treatments as assessed by conventional and digital PRs and CBCT during a 5-year follow-up period. They suggested that CBCT was more sensitive than PRs for the visualization of periapical lesions in a long-term evaluation. Liang et al. [41] compared the quality of root canal treatment using PRs and CBCT in teeth with vital pulps. They found that the treatment outcome, length and density of root fillings and outcome predictors as determined using CBCT differed from the corresponding values determined using PRs. CBCT detected periapical lesions in 25.9% of the teeth, compared with 12.6% using PRs. Root fillings with voids and unsatisfactory coronal restorations negatively influenced the outcome.

### **Assessment of vertical root fracture, resorption**

While root fractures are less common than fractures of the crown and occur in only 7% or fewer of dental injuries, [42,43] they are difficult to diagnose accurately using conventional radiography. Numerous authors have illustrated the usefulness and importance of CBCT in the diagnosis and management in specific aspects of dento-alveolar trauma, especially root fractures [44-46], luxation and/or displacement, and alveolar fracture [47]. CBCT has found particular application for the diagnosis of root fractures (Fig.5.5). Identifying the presence of vertical root fracture (VRF) is often an endodontic challenge. Radiographic features suggestive of VRF such as J-shaped and halo-shaped radiolucencies do not appear until significant bone destruction has occurred and similarly shaped radiolucencies may manifest themselves in cases of apical periodontitis not associated with VRF. Four standard procedures have been described to allow a correct and definitive diagnosis [48]: a visualization during an exploratory surgery [48], a visualization after tooth extraction, [48] a radiographic visualization as long as there is a separation of fragments [48] and a Cone Beam Computer Tomography visualization of the fracture [49,50]. Ex vivo studies have demonstrated that CBCT is more sensitive than conventional radiography in the detection of vertical fractures in roots. However, care should be taken when assessing root filled teeth for VRF using CBCT as scatter produced by the root filling or other high-density intraradicular material may incorrectly suggest the presence of a fracture [8]. Nair, Mandlik et al published clinical case reports in which the elusive VRF was diagnosed using CBCT [8].

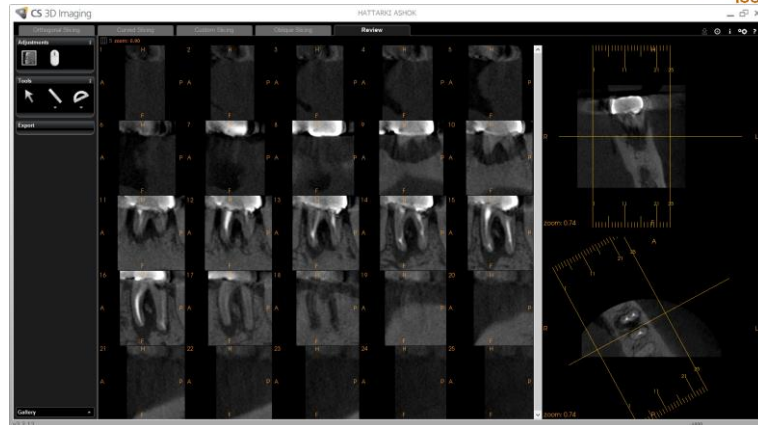
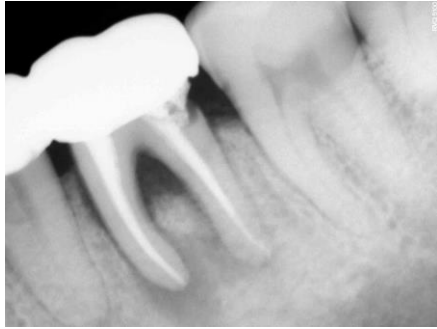


Fig: 3.1. Diagnostic radiograph Fig 3.2 CBCT image showing axial and sagittal sections and fracture on mesial root Courtesy Dr. Nair

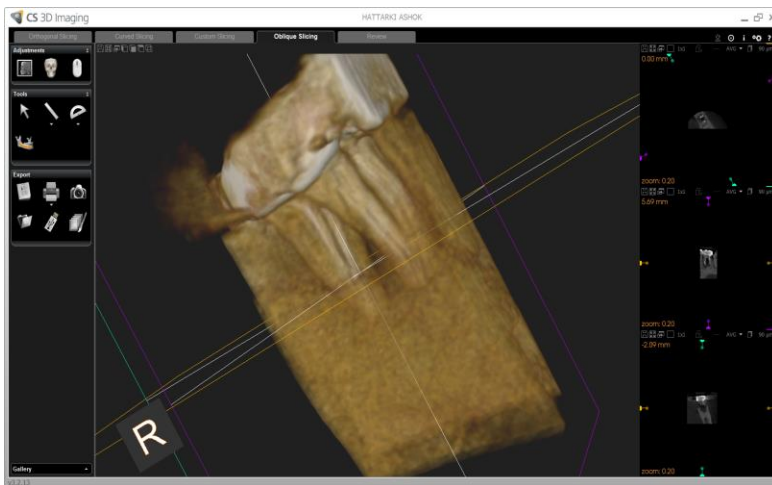


Fig: 3.3 CBCT image showing oblique section and fracture on mesial root Courtesy Dr. Nair

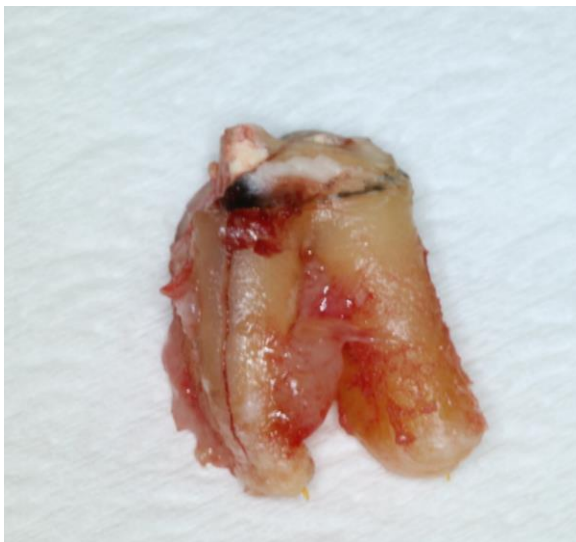

Fig: 3.4. Fracture evident after extraction Courtesy Dr. Nair

### Root Resorption

Root resorption is defined as the loss of dental hard tissues as a result of osteoclastic activities [51]. Resorptive defects may spread within the root in all directions, and their sizes and the positions of radiolucency may not be detected on the radiograph (Fig. 3A and B) [52]. Although intraoral radiography is reasonably accurate in diagnosing internal and external cervical root resorption, CBCT scans enhance the diagnosis of the presence and type of root resorption [53].

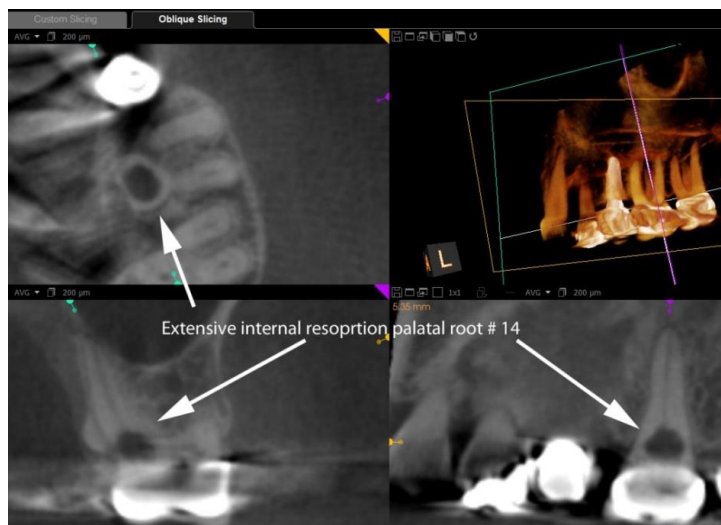


Fig: 4. CBCT showing Internal root resorption

### CONCLUSIONS

In conclusion, CBCT technology aids in the diagnosis of endodontic pathosis and canal morphology, assessing root and alveolar fractures, analysis of resorptive lesions, identification of pathosis of non-endodontic origin, and presurgical assessment before root-end surgery. When compared with medical CT, CBCT has increased accuracy, higher resolution, reduced scan time, a reduction in radiation dose, and reduced cost for the patient [6]. As compared with conventional periapical radiography, CBCT eliminates superimposition of surrounding structures, providing additional clinically relevant information. Drawbacks of CBCT include limited availability, and significant capital investment. As CBCT technology evolves, clinicians will be able to adopt 3-D imaging into their diagnostic repertoire. Because accurate diagnostic information leads to better clinical outcomes, CBCT might prove to be an invaluable tool in the modern endodontic practice. However, endodontic cases should be judged individually, and CBCT imaging should be considered for situations in which information from conventional imaging systems may not yield adequate amounts of information to allow for the appropriate management of endodontic problems.

### ACKNOWLEDGEMENT

We acknowledge Dr. Manoj Nair for extending helping hand while preparing this manuscript and allowing to insert the images of his clinical case in the manuscript.

### CONFLICT OF INTERESTS

The authors declare that they have no conflicts of interest.

### FINANCIAL DISCLOSURE

The cases presented in this article were conducted at an educational institution of the authors and were not supported by any financial assistance.

.

.

## REFERENCES

- [1] Cho PS, Johnson RH, Griffin TW.[ 11995]Cone Beam CT for radiotherapy application. *PhysMedBio* ; 40: 1863 – 83.
- [2] Harrison RM, Farmer FT, The determination of anatomical cross-section using a radiotherapy simulator, *BrJ Radial* 1978 ; 51 : 448 – 53.
- [3] Mozzo P, Procacci C, Tacconi A, Martini PT, Andreis IA. A new volumetric CT machine for dental imaging based on the conebeam technique: preliminary results. *EurRadiol* 1998;8:1558—64.
- [4] Patel S, Dawood A, Whaites E, Pitt Ford T.[ 2009] New dimensions in endodontic imaging: part 1. Conventional and alternative radiographic systems.*IntEndod J*;42:447—62.
- [5] Suomalainen A, Kiljunen T, Ka`ser Y, Peltola J, Kortensniemi M.[ 2009] Dosimetry and image quality of four dental cone beam computed tomography scanners compared with multislice computed tomography scanners. *DentomaxillofacRadiol* ;38:367—78.
- [6] Pauwels R, Beinsberger J, Collaert B, Theodorakou C, Rogers J, Walker A, et al. Effective dose range for dental cone beam computed tomography scanners. *Eur J Radiol* 2012;81:267—271
- [7] Palomo JM, Rao PS, Hans MG. Influence of CBCT exposure conditions on radiation dose. *Oral Surg Oral Med Oral Pathol Oral RadiolEndod* 2008;6:773–82.
- [8] Nair M, Mandlik J, Chaudhari P.[ ;2014] Diagnosing the elusive VRF usingCone Beam CT: Case reports. *IIOABJ* (5)4:30-34
- [9] Vertucci FJ. [1984]Root canal anatomy of the human permanent teeth.*Oral Surgery Oral Medicine and Oral Pathology*. 58(5):589–599.
- [10] Matherne RP, Angelopoulos C, Kulild JC, Tira D.[2008] Use of cone-beam computed tomography to identify root canal systems in vitro. *J Endod*;1:87–9.
- [11] Patel S, Durack C, Abella F, Shemesh H, Roig M, Lemberg K.[ 2015] Cone beam computed tomography in Endodontics — a review. *IntEndod J*;48: 3—15.
- [12] Blattner TC, George N, Lee CC, et al. [2010] Efficacy of cone-beam computed tomography as a modality to accurately identify the presence of second mesiobuccal canals in maxillary first and second molars: a pilot study. *J Endod*;5:867–70.
- [13] Neelakantan P, Subbarao C, Subbarao CV. [2010]Comparative evaluation of modified canal staining and clearing technique, cone-beam computed tomography, peripheralquantitative computed tomography, spiral computed tomography, and plain andcontrast medium-enhanced digital radiography in studying root canal morphology.*J Endod* ;9:1547–1551.
- [14] Bauman R, Scarfe W, Clark S, et al. [2011;]Ex vivo detection ofmesiobuccal canals in maxillary molars using CBCT at four different isotropic voxel dimensions. *IntEndod J* 8:752–878.
- [15] Plotino G, Tocci L, Grande NM, et al. Symmetry of root and root canal morphologyof maxillary and mandibular molars in a white population: a cone-beam computedtomography study in vivo. *J Endod* 2013;12:1545–8.
- [16] Estrela C, Bueno MR, Leles CR, Azevedo B, Azevedo JR. [2008]Accuracy of cone beam computed tomography and panoramic and periapical radiography for detection of apical periodontitis. *J Endod*;34(3):273–279.
- [17] Bender IB, Seltzer S. Roentgenographic and direct observation of experimental lesions in bone, I. *J Am Dent Assoc* 1961;62:152—160.
- [18] Patel S, Dawood A, Mannocci F, et al. [2009]Detection of periapical bone defects in human jaws using cone beam computed tomography and intraoral radiography. *IntEndod J*;6:507–615.
- [19] Lofthag-Hansen S, Huumonen S, Gro`ndahl K, Gro`ndahl HG.[ 2007] Limited cone-beam CT and intraoral radiography for the diagnosis of periapical pathology. *Oral Surg Oral Med Oral Pathol Oral RadiolEndod*;103:114—119.
- [20] Patel S, Wilson R, Dawood A, Mannocci F. [2012]The detection of periapicalpathosis using periapical radiography and cone beam computed tomography - part 1: preoperative status. *IntEndod J* ;8:702–710
- [21] Sogur E, Grondahl HG, Baksı BG, Mert A. Does a combination of two radiographs increase accuracy in detecting acid-induced periapical lesions and does itapproach the accuracy of cone-beam computed tomography scanning? *J Endod*2012;2:131–6.
- [22] Sogur E, Baksı BG, Grondahl HG, et al. Detectability of chemically induced periapical lesions by limited cone beam computed tomography, intra-oral digital andconventional film radiography. *DentomaxillofacRadiol* 2009;7:458–64.
- [23] Tsai P, Torabinejad M, Rice D, Azevedo B. Accuracy of cone-beam computed tomographyand periapical radiography in detecting small periapical lesions.*J Endod* 2012;7:965–790
- [24] Kamburoglu K, Kilic C, Ozen T, Horasan S.[ 2010] Accuracy of chemically created periapical lesion measurements using limited cone beam computed tomography. *Dentomaxillofac Radiol*;2:95–99.
- [25] Bender IB, Seltzer S.[ 1961] Roentgenographic and direct observationof experimental lesions in bone, II. *J Am Dent Assoc*;62:708—16.
- [26] Schwartz SF, Foster JK.[1971] Roentgenographic interpretation ofexperimentally produced bone lesions. *Oral Surg Oral Med Oral Pathol*;32:606—612.
- [27] Cotton TP, Geisler TM, Holden DT, Schwartz SA,[ 2007] Schindler WG.Endodontic applications of cone-beam volumetric tomography.*J Endod*;33:1121—1132.
- [28] Patel S.[ 2009] New dimensions in endodontic imaging: part 2. Cone beam computed tomography. *IntEndod J*;42:463—75.
- [29] Patel S, Wilson R, Dawood A, Foschi F, Manocci F.[2012] The detection of periapicalpathosis using digital periapical radiography andcone beam computed tomography — part 2: a 1-year posttreatmentfollow-up.*IntEndod J* 45:711—23.
- [30] Ozen T, Kamburog`lu K, Cebeci AR, Yu`ksel SP, Paksoy CS.[ 2009] Interpretation of chemically created periapical lesions using 2 differentdental cone-beam computerized tomography units, anintraoral digital sensor, and conventional film. *Oral Surg OralMed Oral Pathol Oral Radiol Endod* 107:426—432.
- [31] Patel S, Durack C, Abella F, Shemesh H, Roig M, Lemberg K.[ 2015] Cone beam computed tomography in Endodontics — a review. *IntEndod J*;48: 3—15.
- [32] Low MTL, Dula KD, Bsurgin W, von Arx T. [2008]Comparison of periapical radiography and limited cone-beam tomography inposterior maxillary teeth referred for apical surgery. *J Endod*;34: 557—562
- [33] Low KM, Dula K, B`urgin W, Arx von T. Comparison of periapical radiography and limited cone-beam tomography in posterior maxillary teeth referred for apical surgery.*J Endod* 2008;5:557–562.
- [34] Rigolone M, Pasqualini D, Bianchi L, et al. [2003]Vestibular surgical access to the palatine root of the superior first molar: “low-dose cone-beam” CT analysis of the pathway and its anatomic variations. *J Endod* ;29:773–775.

- [35] Barthel CR, Zimmer S, Trope M. [2004] Relationship of radiologic and histologic signs of inflammation in human root-filled teeth. *J Endod*;2:75–79.
- [36] Katebzadeh N, Hupp J, Trope M. [1999] Histological periapical repair after obturation of infected root canals in dogs. *J Endod*;25:364–368.
- [37] Katebzadeh N, Sigurdsson A, Trope M. [2000] Radiographic evaluation of periapical healing after obturation of infected root canals: an in vivo study. *Int Endod J*;33:60–6.
- [38] Cotti E, Vargiu P, Dettori C, Mallarini G. [1999] Computerized tomography in the management and follow-up of extensive periapical lesion. *Endod Dent Trauma*;15:186–9.
- [39] de Paula-Silva FW, Hassan B, Bezerra da Silva LA, Leonardo MR, Wu MK. [2009] Outcome of root canal treatment in dogs determined by periapical radiography and cone-beam computed tomography scans. *J Endod* 35:723–6.
- [40] Fernández R, Cadavid D, Zapata SM, Alvarez LG, Restrepo FA. [2013] Impact of three radiographic methods in the outcome of nonsurgical endodontic treatment: a five-year follow-up. *J Endod*;39:1097–1103.
- [41] Liang YH, Li G, Wesselink PR, Wu MK. Endodontic outcome predictors identified with periapical radiographs and cone-beam computed tomography scans. *J Endod* 2011;37:326–31.
- [42] Andreasen JO, Andreasen FM. [1994] Classification, etiology and epidemiology. In: Andreasen JO, Andreasen FM, editors. *Textbook and Color Atlas of Traumatic Injuries to the Teeth*. 3rd edition. Copenhagen, Denmark: Munksgaard; pp. 151–216.
- [43] Cvek M, Tsielingaris G, Andreasen JO. [2008] Survival of 534 incisors after intra-alveolar root fracture in patients aged 7–17 years. *Dental Traumatology*. 24(4):379–387.
- [44] Tyndall DA, Rathore S. [2008] Cone-beam CT diagnostic applications: caries, periodontal bone assessment, and endodontic applications. *Dental Clinics of North America*. 52(4):825–841.
- [45] Hassan B, Metska ME, Ozok AR, van der Stelt P, Wesselink PR. [2009] Detection of vertical root fractures in endodontically treated teeth by a cone beam computed tomography scan. *Journal of Endodontics*.;35(5):719–722.
- [46] Kajan ZD, Taromsari M. Value of cone beam CT in detection of dental root fractures.
- [47] Cohenca N, Simon JH, Roges R, Morag Y, Malfaz JM. [2007] Clinical indications for digital imaging in dento-alveolar trauma—part 1: traumatic injuries. *Dental Traumatology*.;23(2):95–104.
- [48] Scarfe WC, Farman AG. Clinical applications of cone-beam computed tomography in dental practice. *J Can Dent Assoc* 2006;72(1):75–80.
- [49] Edlund M, Nair M, Nair U. [2011] Detection of vertical root fractures by using cone-beam computer tomography: a clinical study. *J Endod*; 37:768–72. Medline
- [50] Hassan B, Metska M, Ozok A, Selt P, Wesselink P. [2009] Detection of vertical root fractures in endodontically treated teeth by cone beam computer tomography scan. *J Endod*; 35:719–722.
- [51] Patel S, Pitt Ford TR. [2007] Is the resorption external or internal? *Dent Update*;34:218–229.
- [52] Estrela C, Bueno MR, de Alencar AHG, et al. [2009] Method to evaluate inflammatory root resorption by using cone beam computed tomography. *J Endod* 11:1491–1497
- [53] Bernardes RA, de Paulo RS, Pereira LO, et al. [2012] Comparative study of cone beam computed tomography and intraoral periapical radiographs in diagnosis of lingual-simulated external root resorptions. *Dent Traumatol*;4:268–272.

## ABOUT AUTHORS

**Dr. Rakhee Modak** is Assistant professor & post graduate student in the department of Oral Medicine and Radiology at Bharati Vidyapeeth Deemed University's Dental College and Hospital Pune, India

**Dr. Shubhangi Gaikwad** is postgraduate student in the department of Oral Medicine & Radiology at Bharati Vidyapeeth Deemed University's Dental College and Hospital Pune, India

**Prof. Dr. Amit Mhapuskar** is Head of the Department and postgraduate guide in the department of Oral Medicine & Radiology at Bharati Vidyapeeth Deemed University's Dental College and Hospital, Pune.

**Dr. Jyoti Mandlik** is Associate professor & Postgraduate guide in department of Conservative Dentistry & Endodontics at Bharati Vidyapeeth Deemed University's Dental College and Hospital, Pune.