

EFFICIENT IDENTIFICATION OF DESICCATED LUMBAR IVD FROM MRI

Leena Silvester¹ and Mathusoothana S Kumar²¹Computer Science Department, College Of Engineering, Attingal, Thiruvananthapuram, INDIA²Information Technology Department, Noorul Islam University, INDIA

ABSTRACT

Segmentation of Intervertebral disc (IVD) plays an important role in clinical diagnosis of lower back pain. Automatically segmenting the IVD in Magnetic Resonance Imaging (MRI) image is extremely challenging as variations in soft tissue contrast and radio-frequency (RF) in homogeneities cause image intensity variations. This paper proposes connected component analysis on intervertebral discs of mid-sagittal MRI data and detection of the abnormal disc. This approach uses union-find algorithm to determine the final label for each pixel. In the initial phase, each pixel is assigned a temporary label. During the final phase, it scans the image and converts the entire provisional label into final. Label associated with the root is having minimum label and it is finalized as the final label. This is the simplest approach and it takes less time to detect a disc as degenerative or not. This proposed algorithm is able to identify the number of lumbar disc which is degenerative. Also by means of visual inspection, we are able to identify the disc is degenerative or not. Here, the degenerative disc is L5-S1 which can be determined visually since it is broken. Localization of intervertebral discs is to locate the intervertebral discs by a point within a bounding box around the discs. The width, height, diameter of the degenerative disc is less than all other disc. Making use of these various statistics and the intensity profile we show that L5-S1 is degenerative. Experimental results show that the proposed method is very efficient and robust with respect to image slices.

Published on: 08th– August-2016

KEY WORDS

Intervertebral Disc
Degeneration; Lumbar
Segmentation; Connected
Component, Localisation of IVD

*Corresponding author: Email: leenasilvester@gmail.com Tel.: +91-9486856119

INTRODUCTION

The most common health problem, low back pain is having high prevalence increases with age. Also, most studies have found that both the mean and median prevalence of low back pain was higher in women. From some studies it is also found a higher prevalence amongst older women as compared with older men [1]. Two studies observed that the occurrence of the low back pain is due to obesity or high body mass index (BMI) [2,3]. The dominant factors influence the onset and course of back pain includes low educational status smoking, obesity, older age, female gender, physically strenuous work, sedentary work, a stressful job, job dissatisfaction and psychological factors such as anxiety or depression, weight, and structural defects of the spinal column[4]. Congenital defects of the vertebrae as well as unequal leg length can cause abnormal loading in the spine. Degenerative spine conditions involve the gradual wear and tear to the discs, joints and bones of the spine over time, usually caused by aging. However, some studies reveal that, there is a correlation between the low back pain between the trauma and nontrauma patients. Low back pain patients with a history of trauma had more severe facet arthrosis than do nontrauma patients[4]. Also there is a scarcity of radiologist [5].

Most widely used imaging modality for the evaluation of intervertebral disc degeneration is the Magnetic resonance imaging (MRI). MRI extracts arbitrary slice orientation including coronal and sagittal views. The type of image “weighting” used during image acquisition determines MR contrast. The most commonly used images for lumbar spine applications are T1-weighted, T2-weighted, intermediate-weighted (proton density), and short tau inversion recovery (STIR). Over a last decade of years, diagnosis of disc degeneration is based on 2D analysis of MR image. T1-weighted images are useful for detection of fat, and fat acts as a natural contrast agent for detection of epidural or paraspinal lesions, marrow infiltration or replacement, focal bone lesions, and also the diagnosis of lipid-containing lesions, especially hemangiomas. In T2-weighted images identifies the bright structures, fluid-containing structures, such as CSF or urinary bladder, and “bright” hyperintense fluid signal. Also, it is useful for the detection of areas of bone marrow edema and is critical for disc related diagnosis. T2-weighted images are useful to show disc desiccation, hyperintensity zones, and Modic end plate findings.

Automatic localization of intervertebral discs from lumbar MRI is the prerequisite to the diagnosis of lower back pain. There has been much progress in research in determining a point within each lumbar disc. The human spine consists of 24 spinal bones, called vertebrae. Lower portion of the spine is known as the lumbar spine. An intervertebral disc, acts like a shock absorber, sits between each pair of vertebrae. Discs are made up of about 80% water, and the water content get decreased as the age progresses, and lose their ability to act as shock absorbers and these discs are known as degenerative. Discs have a tough outer wall (the annulus, a series of strong ligament rings) and a soft center (the nucleus). The nucleus is spongy and provides most of the disc's ability to absorb shock.

Localization of intervertebral discs is to locate the intervertebral discs by a point within or a bounding box around the discs as in [6], while the segmentation task is to provide a fine contour that accurately delineates a contour around the vertebra. Labeling, on the other hand, is to identify the anatomical nomenclature of each structure (e.g. labeling each of the five lumbar vertebrae as L1, L2, L3, L4 and L5). Localization and labelling of a sagittal lumbar T2-weighted MRI is shown in **Figure- 1**. Lumbar area is the second last area of the vertebral column; which are the weight-bearing portion of the spine. The lowest lumbar vertebra is L5 and the highest is L1. Intervertebral discs are labelled based on the enclosing vertebrae [14].

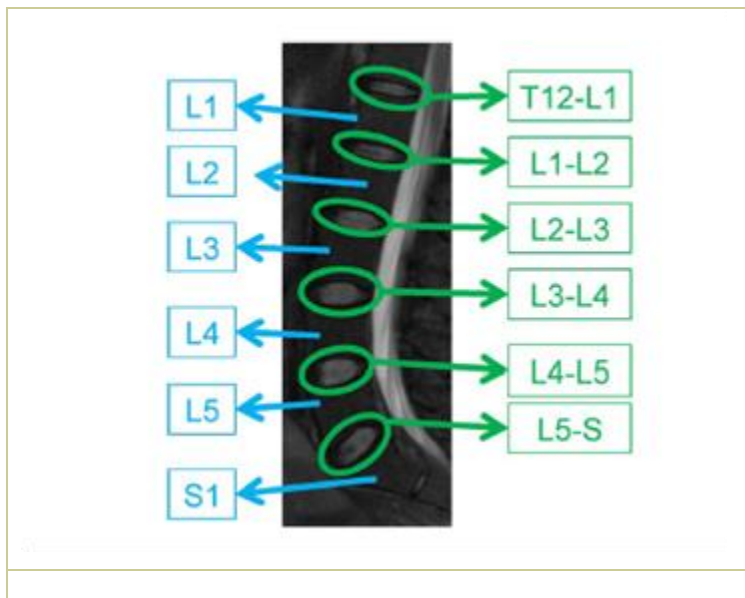


Fig: 1. T2-Weighted MR sagittal view of lumbar region showing lumbar vertebrae (L1-L5) and the six discs connected to them (T12-L1 down to L5-S). The disc L5-S is sometimes called L5-S1 [10].

Normal IVD looks like a saturated oval while the degenerative IVD appears to be dry and flat oval shaped. The rest of the paper is organized as follows: Section II, briefly review of segmentation of intervertebral disc and the localization and labeling of lumbar disc. Section III explains the proposed method. Some of the experimental results are shown in Section IV. Results are discussed in section V. Finally, in Section VI we give our conclusion remarks.

STATE OF THE ART AND CONTRIBUTION

Peng et al. [7] proposed an automatic segmentation of the whole spine column. The procedure relies on intensity profile of the intervertebral disc by convolving it with the image. After fitting all discs on the template, disc centers are searched and then vertebral centers and it is extracted. They tested their technique only on 5 subjects, but the performance of the method for low quality scout data, or when local disc detection fails, is unclear. Weiss et al. [8] propose a semi-automatic approach for localizing and labeling the intervertebral discs. This algorithm is applied separately on upper and lower halves of the spine. The user will manually select a single seed point in the C2-3 disc and detects the remaining discs using intensity threshold values, filters and noise suppression operators. The success of this method is dependent on imaging quality and thresholding values. Zheng et al. [9] develop an approach to segment lumbar vertebrae from digital video fluoroscopic images and validated on synthetic data and a single in vivo sequence. These images are noisier than the standard MR radiographs but have a time component. Fourier descriptors were used to describe the vertebral body shape. This description was incorporated within Hough Transform algorithm. Masaki et al. [10] presents a procedure for automated localization the spine and the discs

based on intensity and a line detection filter to find the straight line between the spinal cord and the ID with the Hough transform. With the help of five radiologists they validated 9 out of 10 cases that the automatic image plane is better than manual. A more recent study has been done by Pekar et al. [11] for the automatic detection of intervertebral discs in 3D MR scout scans as part of scan geometry planning (a step beyond selecting a particular slice from an existing scan). They used a 2D image filter for disc candidate detection are located by a filter using eigenvalues analysis of the image Hessian matrix, followed by 3D connected components to find disc centers. They use a clever search is to locate the next disc through the candidates by distance constraint. If a disc is absent, new point is introduced and it is interpreted as missing disc due to abnormality. Chwialkowski et al. [12] introduce a heuristic-based procedure for automated localization of discs, vertebrae, and spinal cord analysis of the pattern of changes in grey intensities along the disc, and they also compared the variation of gray level intensities in healthy and damaged discs. Schmidt et al. [13] presents a probabilistic inference method using a part-based model to localize and label intervertebral discs in 3-D full back MR images. It incorporates appearance and shape information and uses the A* algorithm for efficiently pruning the search space. This estimate is computed by exact inference on a tree-structured subgraph and guarantees global optimum. Alomari et al. [14, 15] proposed a graphical model for the lumbar disc localization that captures both pixel- and object-level features [14]. Using a Gibbs distribution, their model assumes local and global levels. Spatial information at the pixel level (global level latent variables) and at the object level (local latent variable), they model the spatial distribution of the discs and the relative distances. They use generalized expectation-maximization for optimization, which achieves efficient convergence of disc labels. They use a probabilistic model for automatic localization and labeling of the discs and outputs in a point inside each disc [15]. They orient each disc horizontally and then they use an Active Shape Model [16] to get a bounding box of each disc and extract intensity and texture features from each disc. Then they construct five classifiers and a voting scheme by running heterogeneous learning algorithms (SVM, PCA+LDA, PCA+Naive Bayes, PCA+QDA and PCA+SVM) [17] to detect a herniated disc. Ayse Betul Okay et al. [18] labels the lumbar vertebrae and discs together simultaneously employ a second-order MRF chain in our current work. The local image features are extracted from the image by employing Pyramid Histogram of Oriented Gradients (PHOG) and a novel descriptor image projection descriptor (IPD). These features are trained with Support Vector Machines (SVM) and each pixel in the target image is locally assigned a score. These local scores are combined with the semi-global geometrical information like the distance ratio and angle between the neighboring structures under the Markov Random Field (MRF) framework. Their work can handle the missing structures in the MR images. Michopoulou et al. [19] demonstrated the classification of intervertebral discs into normal or degenerated using a Fuzzy C means algorithm in conjunction with atlas approach for spine MRI images which combines prior anatomical knowledge by means of a rigidly registered probabilistic disc atlas with fuzzy clustering techniques incorporating smoothness constraints. Combined algorithm minimizes the severe leakage of disc border due to the overlapping grey-level values between disc and surrounding tissues. Alomari et al. [20] does a survey of the localization, labeling, and segmentation problems for the various vertebral column structures from the available medical imaging modalities. Subarna Ghosh et al. [21] propose a tight bounding box for each disc after localization method. They computed HOG (Histogram of Oriented Gradients) features along with SVM (Support Vector Machine) as classifier to achieve 99% disc localization accuracy on 53 clinical cases. Bhole et al. [22] proposed an automatic detection of lumbar vertebrae and extract a rough ROI and finally the tight bounding box for each disc. They achieve 98.8% accuracy for disc labeling on 67 sagittal images.

In most of the previous research, researchers have been focused on finding a point inside the disc, which is a prerequisite of challenging segmentation step in order to diagnose a disc abnormality. In our work we provide tight bounding boxes for each disc in the lumbar region so that we automatically provide diagnostic results after complicated segmentation.

METHODS

We present a fully automated method of accessing quantitatively from mid-sagittal MRI.

Image preprocessing

Preprocessing of the image starts with enhancing the image. The noise and low contrast responsible for these failures are the fundamental obstacles to successful automatic segmentation of MRI images. In order to reduce the random noise we apply 3*3 median spatial filters. Median filters will not blur the edges as much as a comparable linear low pass filters

Image Normalization

Image normalization tries to reduce the effect of variation in the input images. Two common methods of normalization are contrast stretching and histogram equalization. Contrast stretching applies a linear transformation to the input image so that the intensity histogram is stretched across the full range of possible pixel intensity values. Image normalization also tries to resize the input image using either nearest-neighbor interpolation or bilinear interpolation or bicubic interpolation. When the specified output size is smaller than the size of the input image and method is 'bilinear' or 'bicubic', resizing applies a lowpass filter before interpolation to

reduce aliasing. Resizing reduces the processing time. Contrast-limited adaptive histogram equalization (CLAHE) was performed as one preprocessing step.

Gradient computation and edge detection

Preprocessing step includes the computation of gradient of the image. Change of image occurs at the boundary and gradient is used to find the boundary. Magnitude of the gradient describes how quickly the image changes in either x or y direction. Therefore, edge detection with Sobel operator is applied in $-x$ and $-y$ directions.

Connected Component analysis

Connected Component analysis is done in 3 phases; pre-scanning phase, analysis phase and scanning phase. In the first phase, pre-scanning phase, provisional labels are assigned and building of an equivalence array is maintained. This phase scans pixels and its neighbours (in a distance r are considered) and represent the equivalence information as a rooted tree using union-find algorithm. Union-find algorithm maintains the equivalence information of the provisional labels assigned as a rooted tree. Three operations are needed to implement union-find algorithm: makeset, find and union. The second phase, analysis phase, does not access the image directly. It analyses the union-find algorithm to determine the final label for each pixel. During this phase, it scans the image and converts the entire provisional label into final. Label associated with the root is having minimum label and it is finalized as the final label.

Algorithm

To achieve fully automatic intervertebral disc location from a set of sagittal image slices, the following procedure is to be performed.

Algorithm 1: Connected Component analysis-Algorithm

1. Scan the image, left to right, top to bottom
2. If the pixel is 1, then
 - (a) If only one of its upper and left neighbours has a label then copy the label
 - (b) If both have the same label, then copy the label
 - (c) If both have different label, build an equivalence array and form the union of those two pixels by making the root node of one of the pixels point to the root node of the other.
 - (d) Otherwise, assign a new label to this pixel and enter this label in equivalence table
3. Repeat Step 2 until no nonzero pixels are left and the equivalence classes are completely determined

During the second pass, scan the image, left to right, top to bottom and find the lowest label for each equivalence set in the equivalence array. Scan the image for the second time and replace each label by the root i.e., Assign each pixel the label of the equivalence class

To achieve fully automatic intervertebral disc location from a set of sagittal image slices, the following procedure is to be performed.

Algorithm 2: Segmentation of IVD

Step 1: Let us consider a set of N sample spine images $X \in \mathfrak{R}$, where $X = \{x_1, x_2, \dots, x_N\}$ taking values in an N -dimensional image space and \mathfrak{R} represents universe. Assume each image $x_i \in \mathfrak{R}$, have a sequence of sagittal image I_1, I_2, \dots, I_k .

Step 2: Select a best MR image slice I_i from a sequence of sagittal image $\zeta = \{I_1, I_2, \dots, I_k\}$ in order to save processing time and achieve better detection results.

Step 3: Preprocessing can be carried out on this slice.

Step 4: Normalization enhances the contrast of the image by transforming the values using contrast-limited adaptive histogram equalization (CLAHE) and then resize the image

Step 5: Compute the gradient of the image.

Step 6: Remove all connected components from the binary image.

Step 7: Perform connected component analysis on the binarized preprocessed image to locate and labeling all the visible intervertebral discs (IVD) in the best slice I_i .

Step 8: Search for missing discs in other slices $I_i \in \zeta$.

Step 9: Calculate the length and width of minimum bounding rectangle of each intervertebral disc.

Step 10: Calculate $H_{avg} = T_p / t$ where t is the height of the IVD and T_p is the sum of the pixels of the height of each IVD

Step 11: Calculate minimum height H_{min} and check with threshold value for abnormal condition.

RESULTS

This database is freely available from spine web [23] and it was used to detect vertebrae and intervertebral disc (DataSet 7 in the webpage) [24]. The dataset contains 15 T2-weighted turbo spin echo MR images and the reference manual segmentation.

Quality analysis

Before quantitative analyses, the quality of the segmentations was visually within the first 2 seconds of the visual inspection. Input image is represented in **Figure-2**. Boundaries of the disc are identified and plotted in **Figure-3**. It is noted that the last disc L5-S1 is broken into two regions and it is identified as degenerative. Localisation of disc is shown in **Figure-4** after identifying the disc and the application of the algorithm.

Quantitative analysis

Table-1 shows various statistic of IVD. The height, width, standard deviation and area of the discs are calculated and plotted in **Figure-5 to Figure-8**.

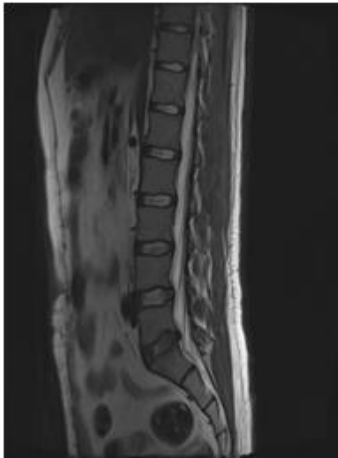


Fig: 2. Input Image



Fig: 3. Boundary of Disc

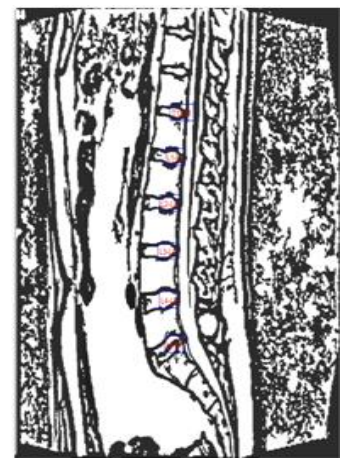


Fig: 4. Localisation of IVD

Standard deviation is a measure that is used to quantify the amount of variation or dispersion of a set of data values. A standard deviation close to 0 indicates that the data points tend to be very close to the mean of the set, while a high standard deviation indicates that the data points are spread out over a wider range of values. So we can conclude that L5-S1 is degenerative since it is having high standard deviation. The width, height, diameter of the disc is also decreased. The width of the degenerative disc is 4.78 which is less than all other disc. The minimum value of height is 4.35, which is the degenerative one. Diameter of the degenerative is less than all other disc and it is 21.56. Statistics of IVD is shown in **Table-1**. Thus; we can conclude that L5-S1 is degenerative

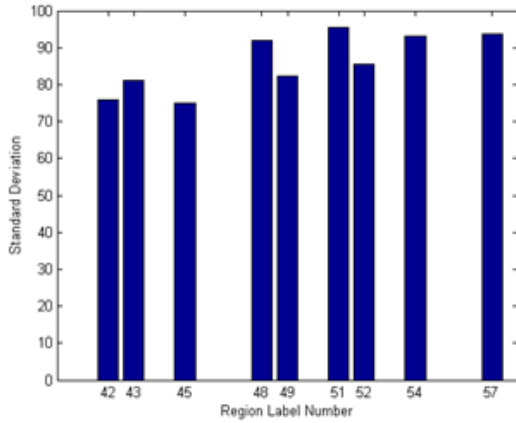


Fig. 5. Standard Deviation

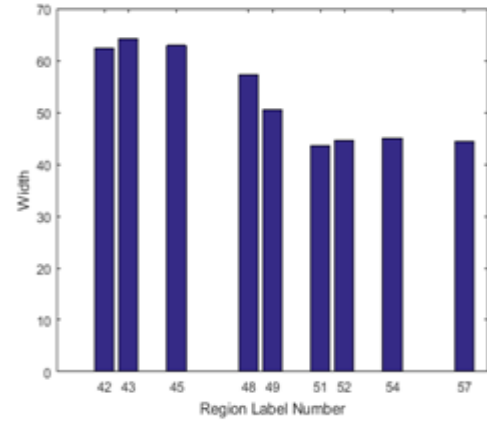


Fig. 6. Width of disc

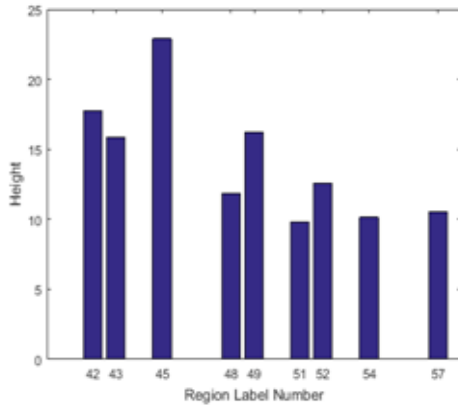


Fig. 7. Height of disc

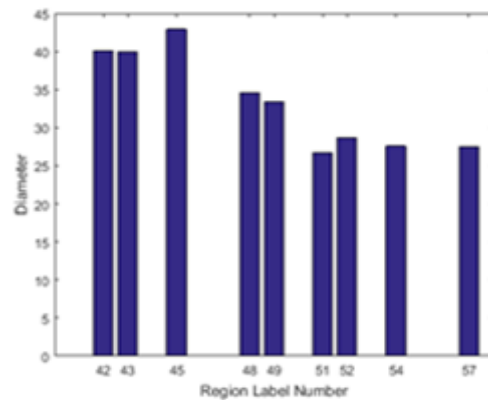


Fig. 8. Diameter of disc

Evaluation of Tissue Properties within the Disc

For a normal healthy disc, the degree of hydration and resultant signal intensity diminishes as one proceeds outward from the geometric center to the peripheral annular fibers. Hence, if we plot the normal distribution of image intensities, it forms an axially symmetrical, bell-shaped curve. With the degenerative disc, the symmetry of the grey intensities is not a bell shaped curve and it is totally disturbed, and the center of the peak is flattened. The peak of IVD is flattened in the [Figure-9](#).

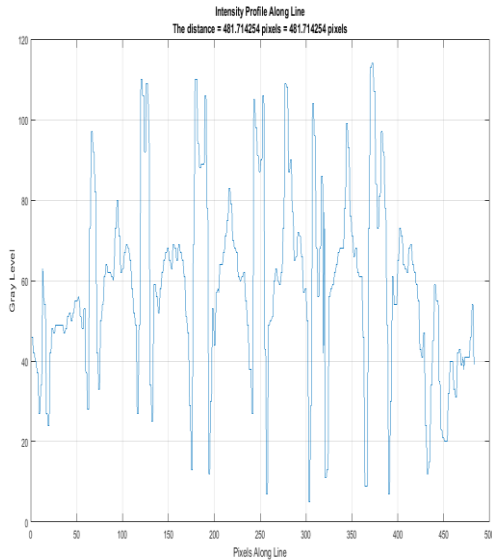


Fig: 9. Intensity profile

Table: 1. Statistics of IVD

Height	Width	Diameter	Standard Deviation
4.78	4.35	21.56	46.39

DISCUSSION

The results are shown in **Figure-3** to **Figure-8**. From this it is clear that the width, height, diameter of the degenerative disc is decreased. The width of the degenerative disc is 4.78 which is less than all other disc. The minimum value of height is 4.35, which is the degenerative one. Diameter of the degenerative is less than all other disc and it is 21.56. Statistics of IVD is shown in Table 1. The intensity profile of the disc is shown in figure 9 which shows that L5-S1 is degenerative Thus; from all the results we can conclude that L5-S1 is degenerative.

CONCLUSION

This proposed work focuses on the 2D segmentation of intervertebral disc. Here, T2 images are the input of the algorithm since recent studies are concentrated on T2 images. This method is a fully automatic and no manual seed selection is required for the working of this procedure. Application of connected component analysis on a preprocessed binary image will result in reliable classification of disc as normal or abnormal while maintaining robustness. Computation time is also less. The result will depend upon the preprocessed image. If the image is a smooth one we may lose a connected component and thus it may lead to missing a disc or algorithm will result in incorrect classification of disc as degenerative or not.

CONFLICT OF INTEREST

Authors declare no conflict of interest.

ACKNOWLEDGEMENT

None.

FINANCIAL DISCLOSURE

No financial support was received to carry out this project.

REFERENCES

- [1] Hoy D, Brooks P, Blyth F, Buchbinder R. [2010] The epidemiology of low back pain. *Best practice & research Clinical rheumatology* 24(6):769-781.
- [2] Vogt MT, Lauerma WC, Chirumbole M et.al. [2002] A community- based study of postmenopausal white women with back and leg pain: health status and limitations in physical activity. *The Journals of Gerontology. Series A, Biological Sciences and Medical Sciences* 57(8):M544–550.
- [3] Webb R, Brammah T, Lunt M. [2003] Prevalence and predictors of intense, chronic, and disabling neck and back pain in the UK general population *Spine* 28(11):1195–202.
- [4] Peterson CK, Bolton JE, Wood AR. [2000] A cross-sectional study correlating lumbar spine degeneration with disability and pain, *Spine* 25(2):218.
- [5] Bhargavan M, Sunshine JH, and Schepps B. [2002] Too few radiologists?. *American Journal of Roentgenology*, 178(5): 1075–1082.
- [6] Ghosh S, Malgireddy MR, Chaudhary V, Dhillon. [2012] G A new approach to automatic disc localization in clinical lumbar MRI: combining machine learning with heuristics. In: *Proceedings of IEEE international symposium on biomedical imaging*: 114–117.
- [7] Peng Z, Zhong J, Wee W, Lee Jh. [2005] Automated vertebra detection and segmentation from the whole spine MR images. In: *Proc. Engineering in Medicine and Biology, IEEE-EMBS 2005*: 2527–2530.
- [8] Weiss KL, Storrs JM, and Banto RB. [2006] Automated spine survey iterative scan technique, *Radiology*.239(1):. 255–262.
- [9] Zheng Y, Nixon MS, Allen R. [2004] Automatic segmentation of lumbar vertebrae in digital videofluoroscopic imaging, 23(1): 45–52.
- [10] Masaki T, Lee Y, Tsai DY, Sekiya M, and Kazam K. [2006] Automatic determination of the imaging plane in lumbar MRI, in *Proc.SPIE Med. Imag* 1252–1259.
- [11] Pekar V, Bystrov D, Heese HS, et al. [2007] Automated planning of scan geometries in spine MRI scans. in *Proc. MICCAI*. New York: Springer, *Lecture Notes Computer Science*,4791:601–608.
- [12] Chwialkowski, MP., Shile, PE., Peshock, RM., Pfeifer, D., Parkey, RW. [1989]: Automated detection and evaluation of lumbar discs in mr images. In: *Proc. of IEEE EMBS*.
- [13] Schmidt S, Kappes J, Bergtholdt M, Pekar V, Dries S, Bystrov D, and Schnörr C. [2007] Spine detection and labeling using a parts-based graphical model. in *Proc. 20th Int Conf Inf Process Med Imag* 4584: 122–133.
- [14] Alomari RS, Corso JJ, and Chaudhary V. [2011] Labeling of lumbar discs using both pixel- and object-level features with a two-level probabilistic model. *IEEE Trans. Med. Imag* 30(1):1–1.
- [15] Corso JJ, Alomari RS, and Chaudhary V. [2008] Lumbar disc localization and labeling with a probabilistic model on both pixel and object features. in *Proc. Med. Image Comput. Comput.-Assisted Intervention Conf vol 5241*: 202–210.
- [16] Cootes T. [1995] Active shape models-their training and application. *Computer Vision and Image Understanding*, 61(1): 38–59.
- [17] MathuSoothana S Kumar, R. and Muneeswaran, K. [2011] An Improved Face Recognition Technique Based on Modular LPCA Approach. *Journal of Computer Science (JCS)*, 7(12):1900-1907.
- [18] Oktay AB and Akgul YS. [2013] Simultaneous localization of lumbar vertebrae and intervertebral discs with svm based mrf. *IEEE TMI*
- [19] Michopoulou S, Costaridou L, Panagiotopoulos E, Speller R, Panayiotakis G, Todd-Pokropek A. [2009] Atlas-based segmentation of degenerated lumbar intervertebral discs from mr images of the spine. *IEEE Trans Biomed Eng.*
- [20] Alomari RS, Ghosh S, Koh ,Chaudhary V. [2015] Vertebral Column Localization,Labeling, and Segmentation. *Spinal Imaging and Image Analysis* 18:193.
- [21] Ghosh S, Malgireddy MR, Chaudhary V, Dhillon G. [2012] A new approach to automatic disc localization in clinical lumbar MRI: Combining machine learning with heuristics. 9th IEEE International Symposium on InBiomedical Imaging (ISBI): 114-117.
- [22] Bhole C, Kompalli S, and Chaudhary V. [2009] Context-sensitive labeling of spinal structures in mri images, in *The Proceedings of SPIE medical imaging*.
- [23] Spineweb. [2013] <http://spineweb.digitalimaginggroup.ca/>, Accessed: 2016-01-29.
- [24] Yao J, Burns JE, Munoz H, Summers RM. [2012] Detection of vertebral body fractures based on cortical shell unwrapping. *Springer in Medical Image Computing and Computer-Assisted Intervention–MICCAI* : 509–516.